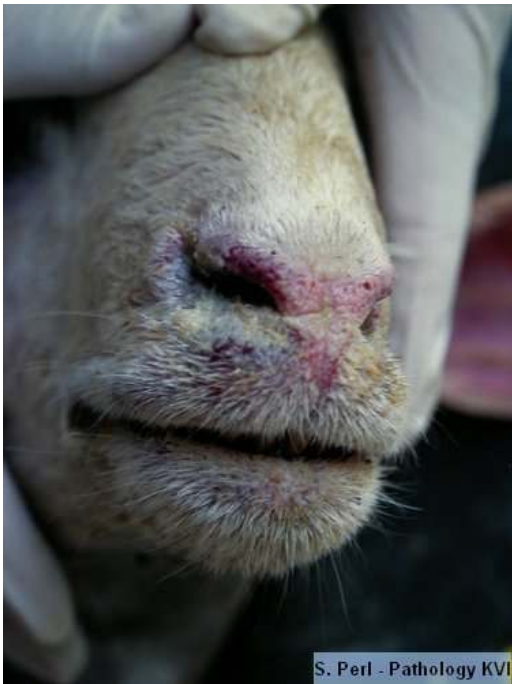
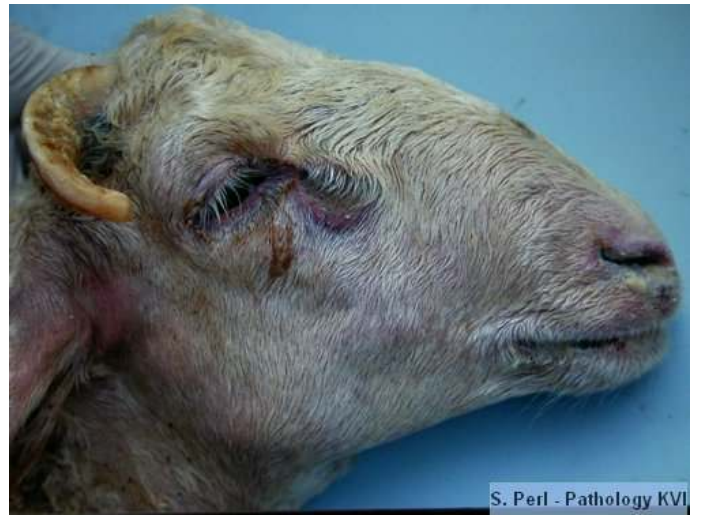
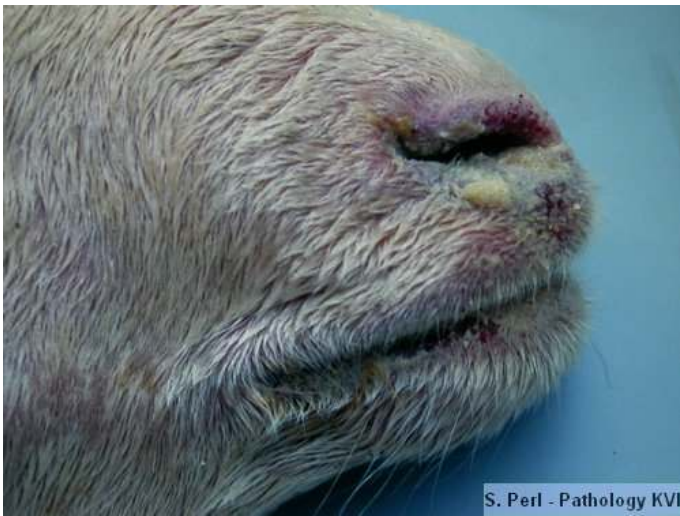Peste des petits ruminants (PPR)



1

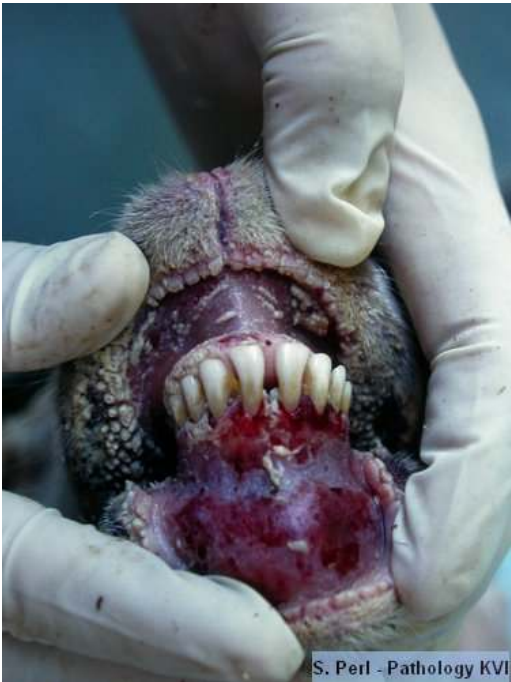

2

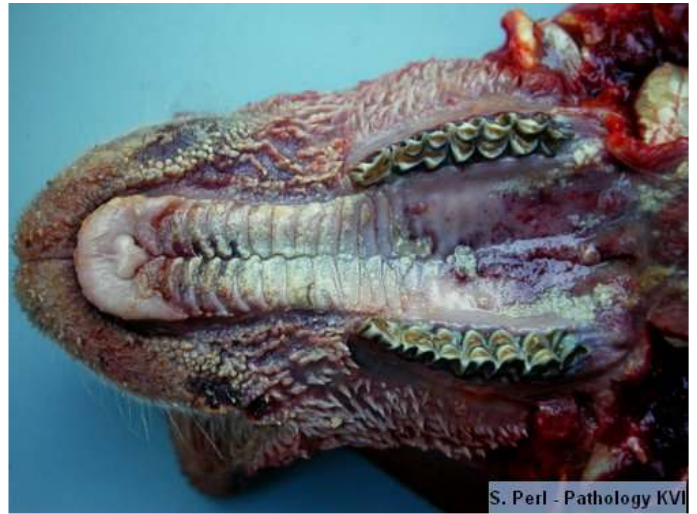

3

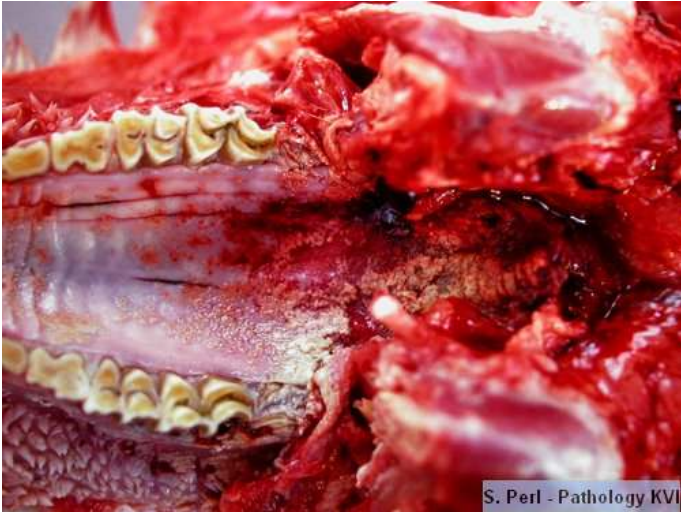1,2,3, Mucopurulent nasal discharge of a sheep



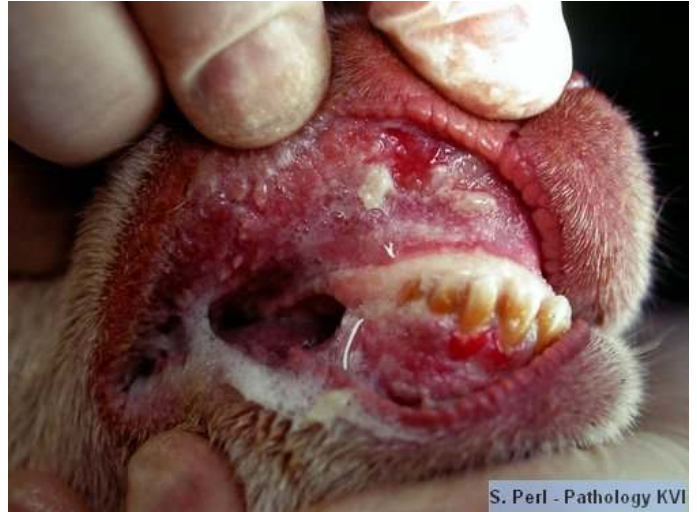4. Multifocal ulcerations flaked with fibrinopurulent exudate on the oral mucosa.



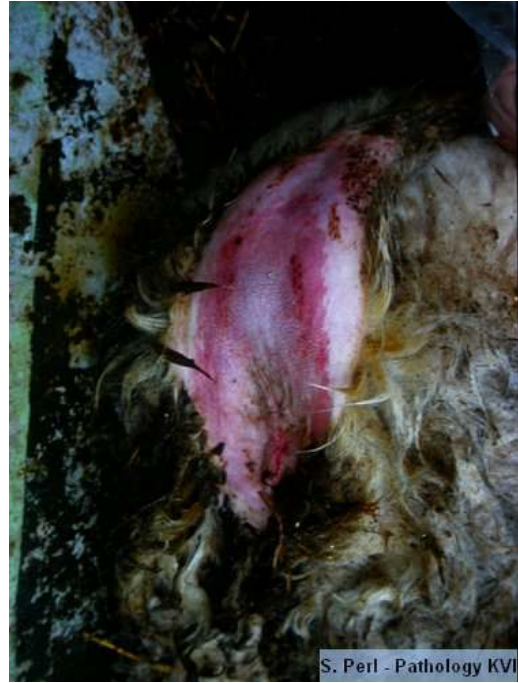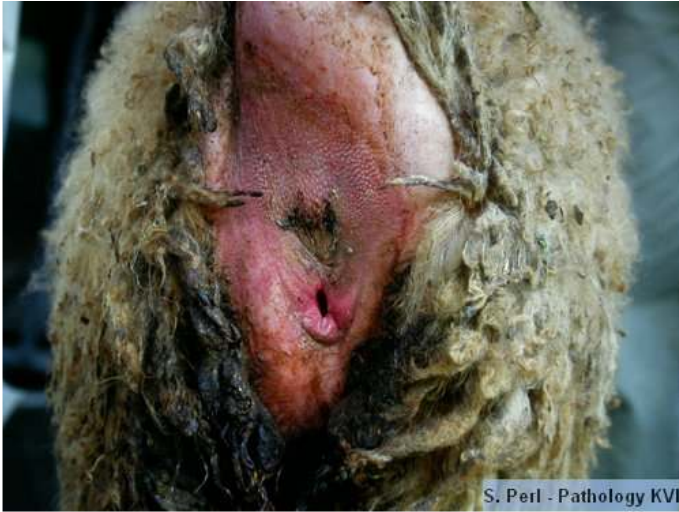5. Multifocal to diffuse ulcerations on the lips, hard and soft palate



6. Multifocal to diffuse ulcerations on the hard and soft palate

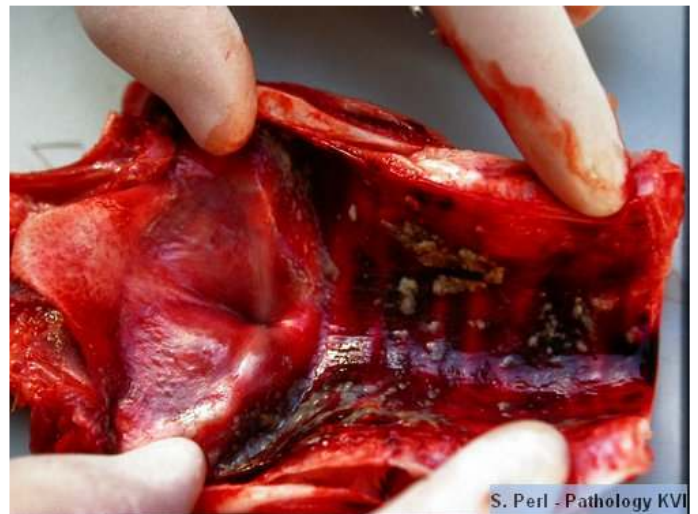
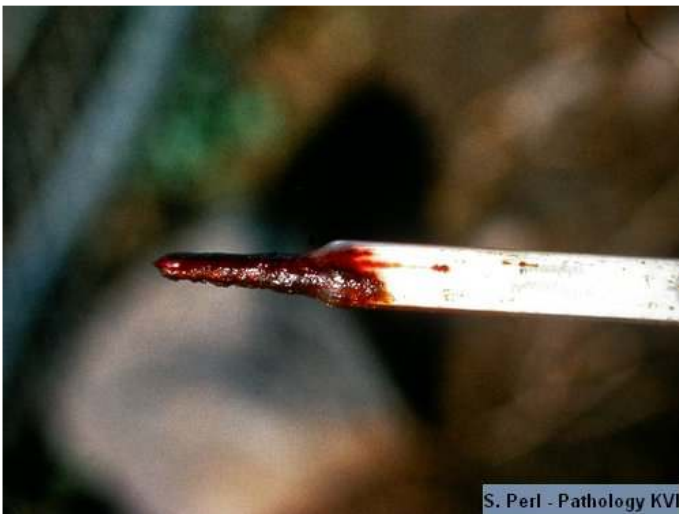
7. Buccal mucosa, congestion and ulceration



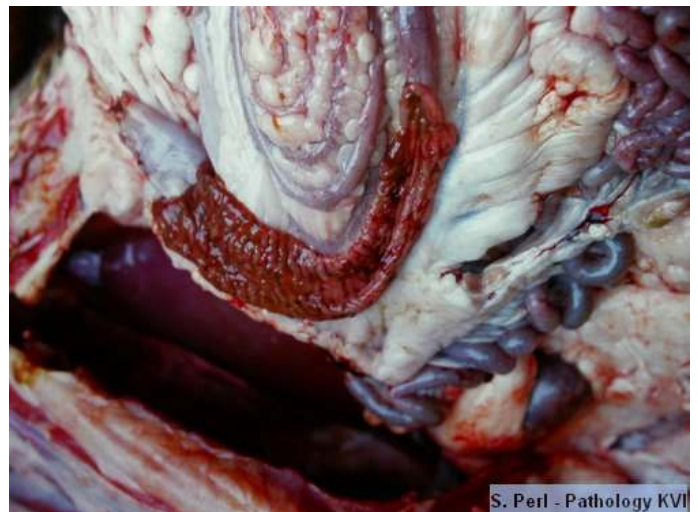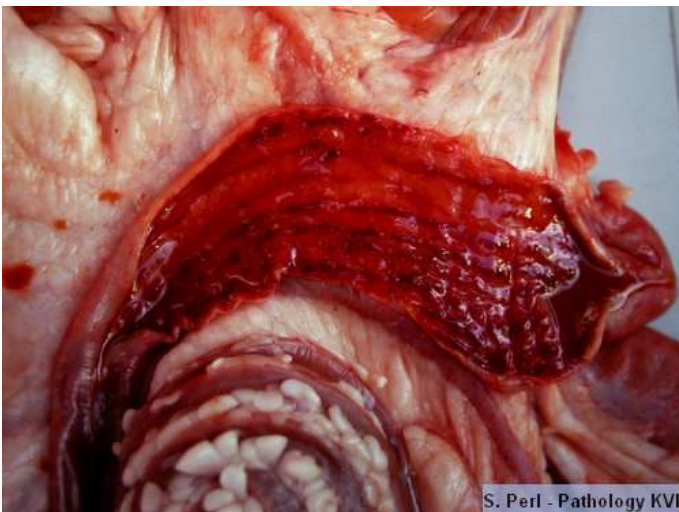
8. Congestion and multifocal ulcerations of the skin under the tail

9. Congestion and multifocal ulcerations of the skin under the tail and hemorrhagic diarrhea



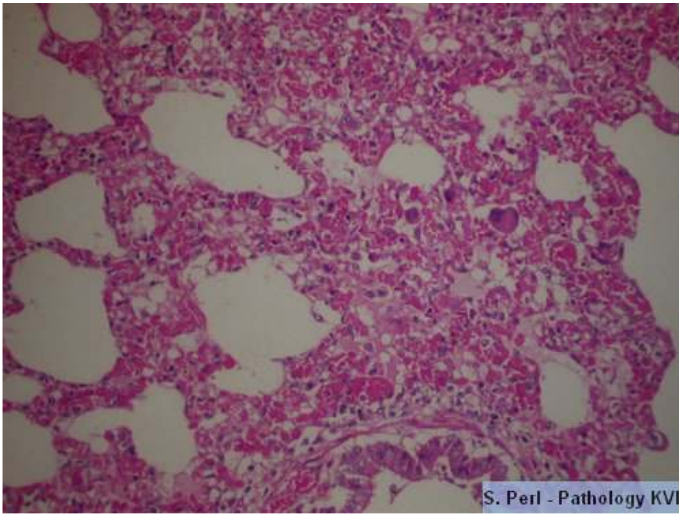
10. Hemorrhagic feces on the thermometer after measuring rectal temperature

11. Congestion and multifocal ulceration of the tracheal mucosa

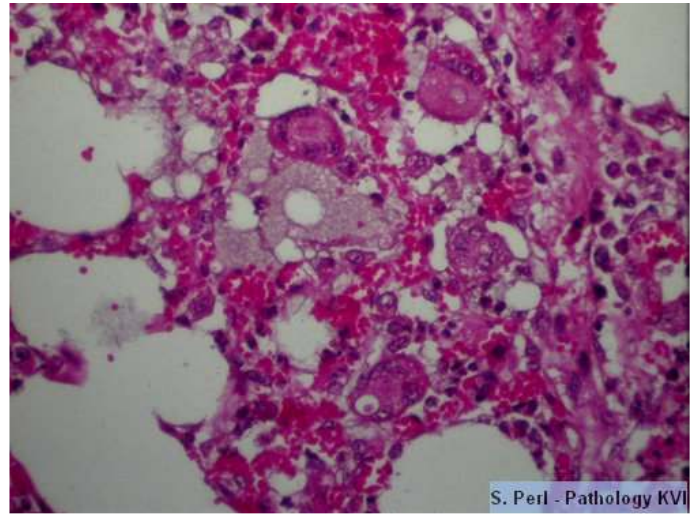


12. Congestion, multifocal ulcerations and blood content in the cecum.

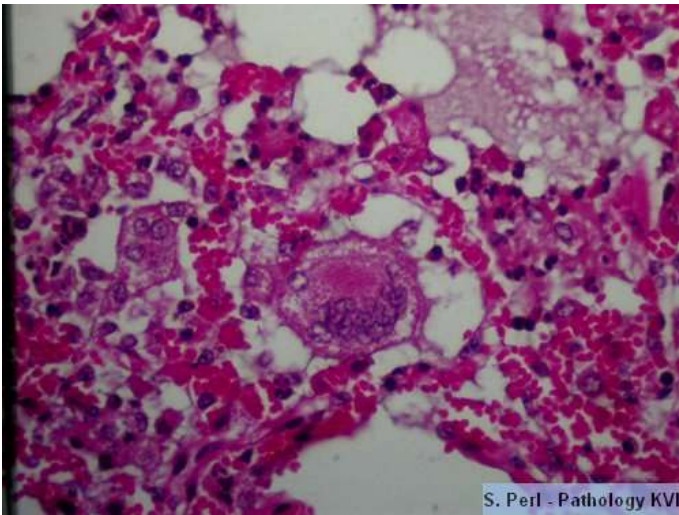
13. Congestion, multifocal ulcerations and hemorrhages on the mucosa of the ascending colon



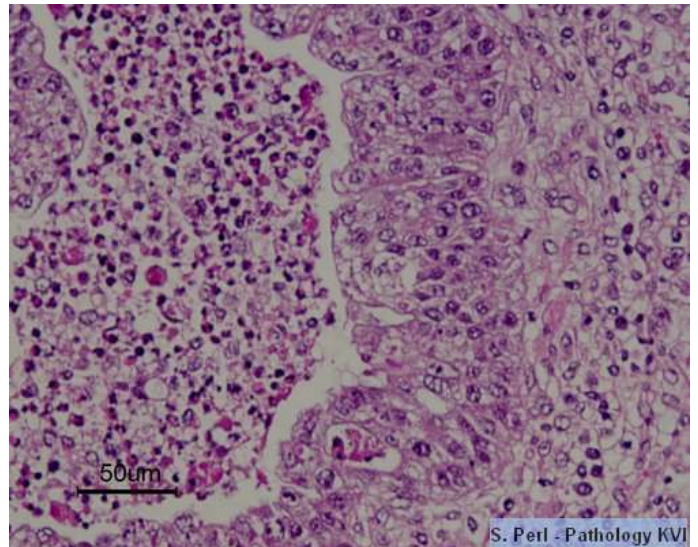
Interstitial pneumonia with alveolar syncytial cells



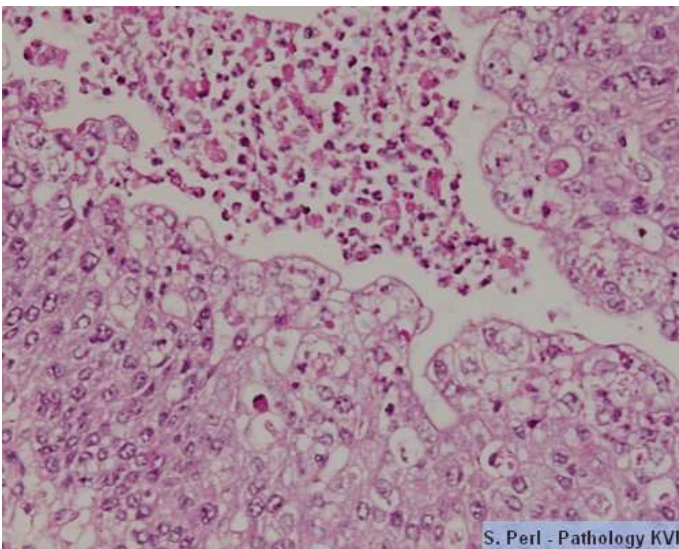
Interstitial pneumonia with alveolar syncytial cells



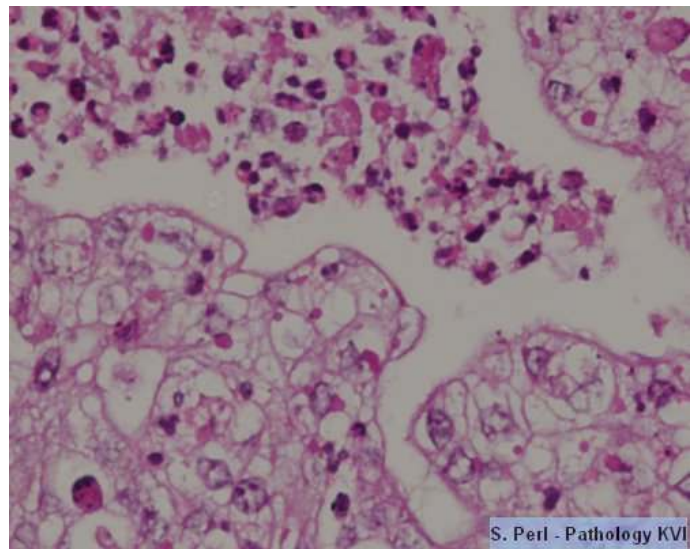
Interstitial pneumonia with alveolar syncytial cells



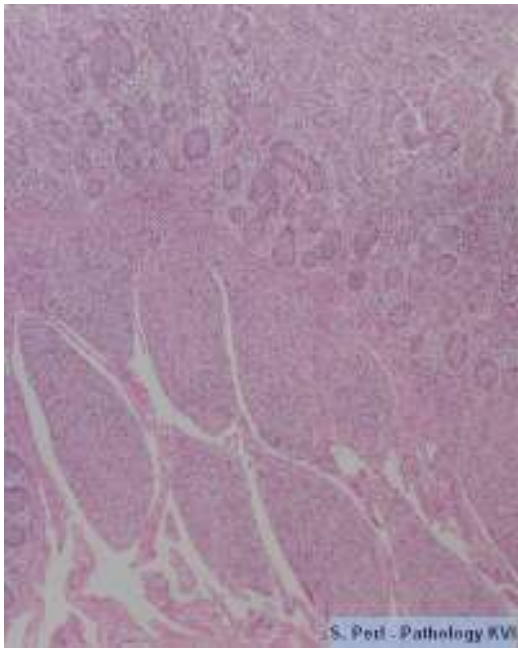
Bronchiolitis, hyperplasia of epithelial cells



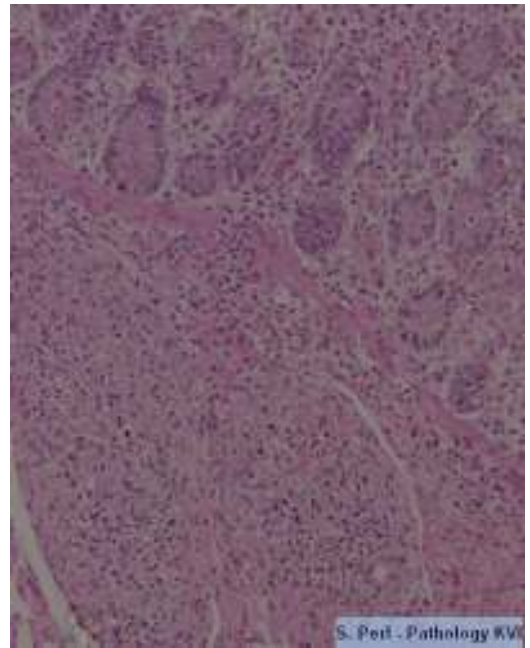
Bronchiolitis, hyperplasia of epithelial cells with intracytoplasmic eosinophilic inclusion bodies



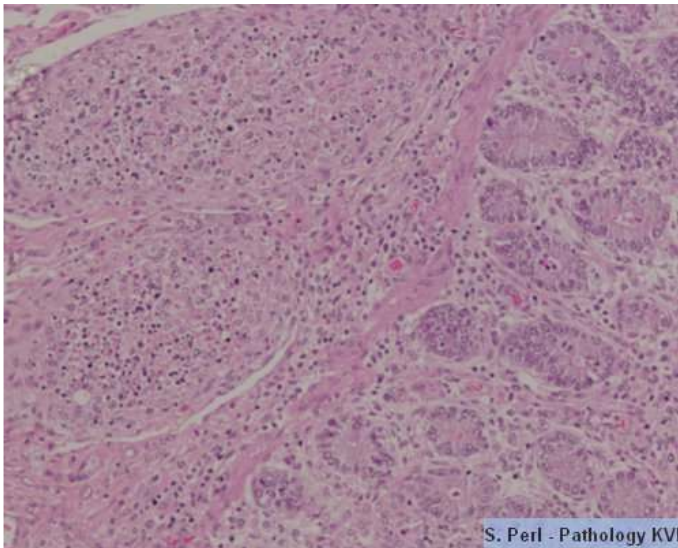
Bronchiolitis, hyperplasia of epithelial cells with intracytoplasmic eosinophilic inclusion bodies



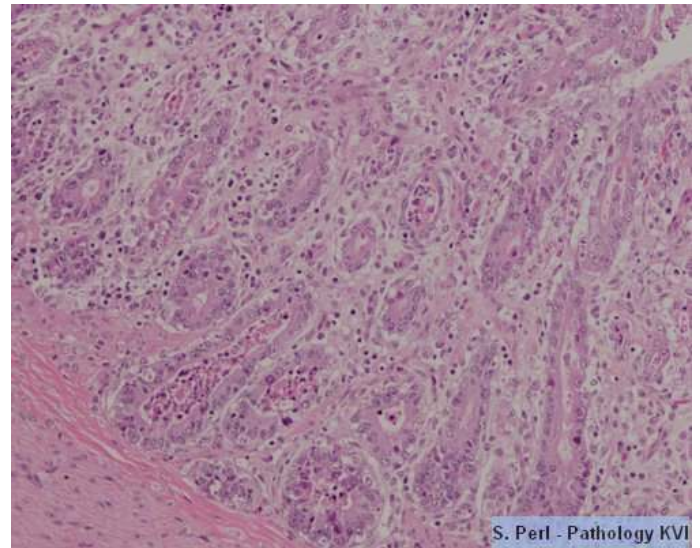
Ileum, sever depletion of Payer's patches



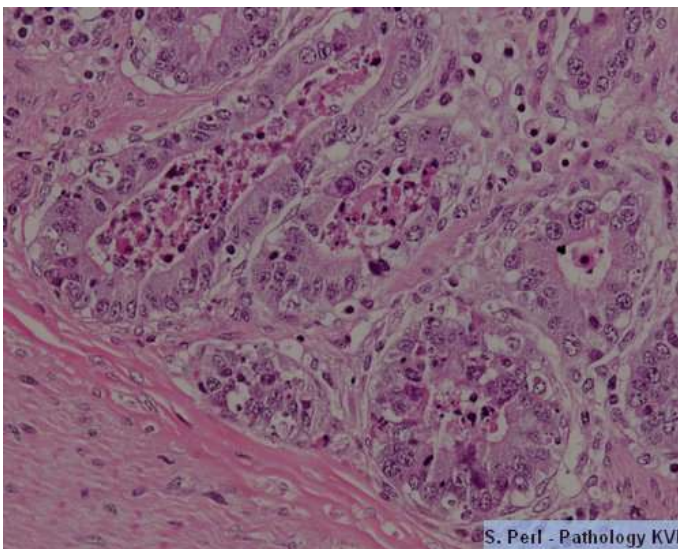
Ileum, sever depletion of Payer's patches



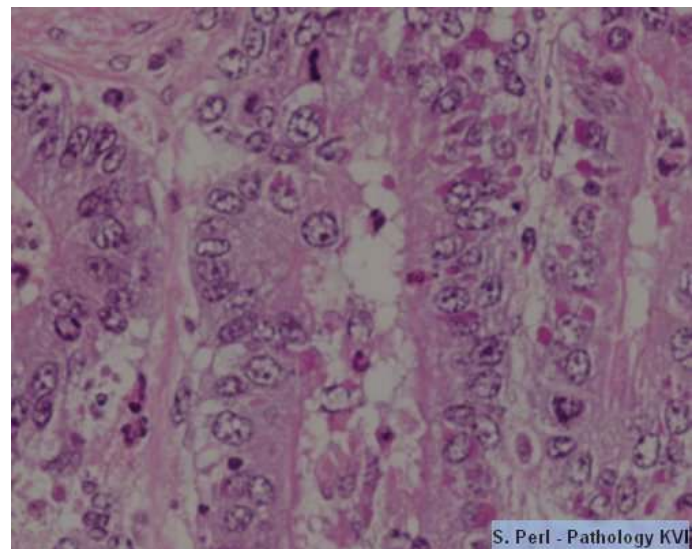
Ileum, sever depletion of Payer's patches



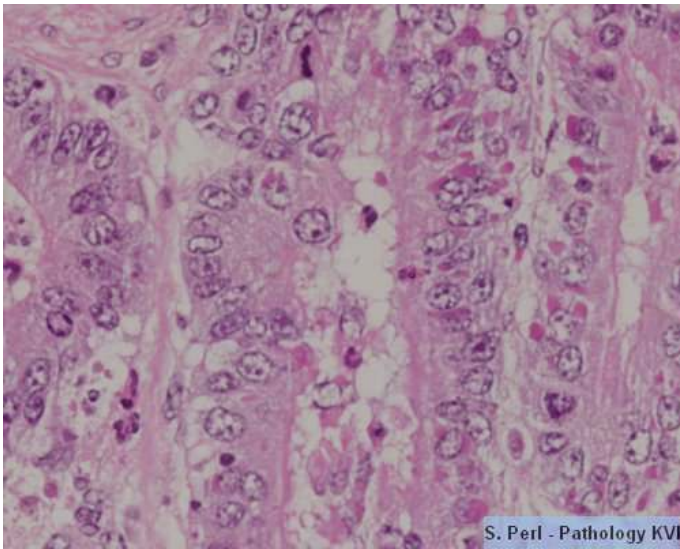
Enteritis with crypt dilation, filed with inflammatory cells and cell debris



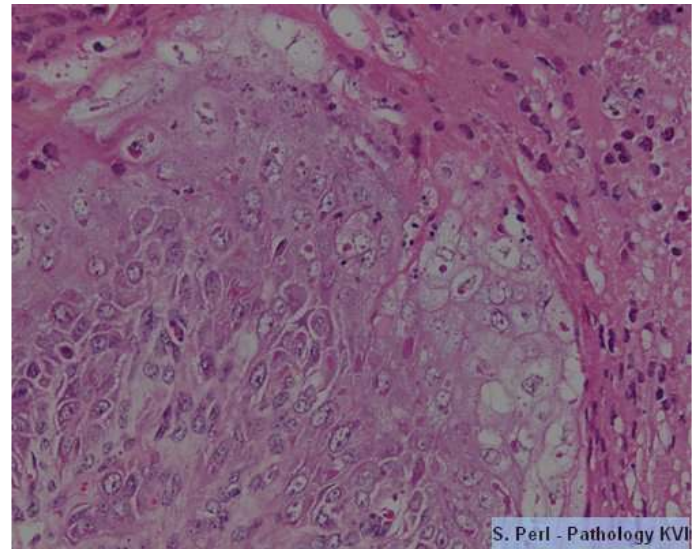
Enteritis with crypt dilation and filed with inflammatory cells and cell debris



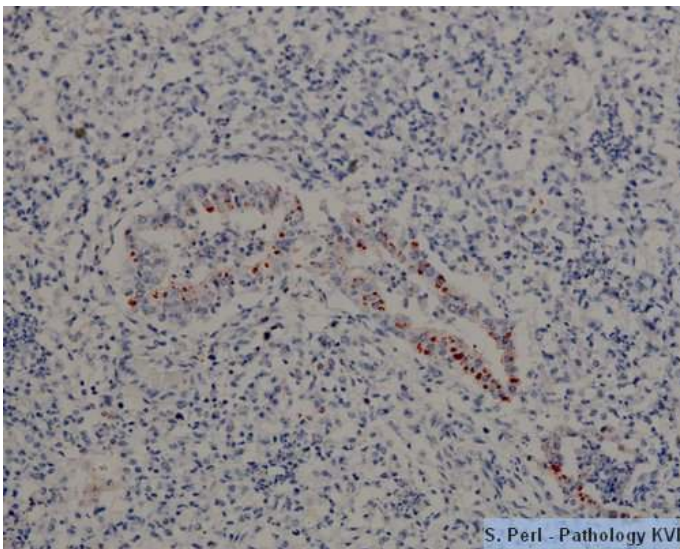
Intestinal crypts with intracytoplasmic eosinophilic inclusion bodies



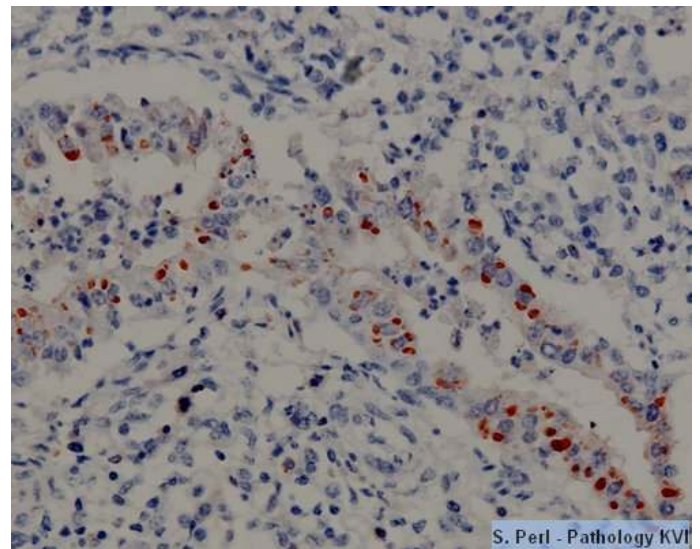
Intestinal crypts with intracytoplasmic eosinophilic inclusion bodies



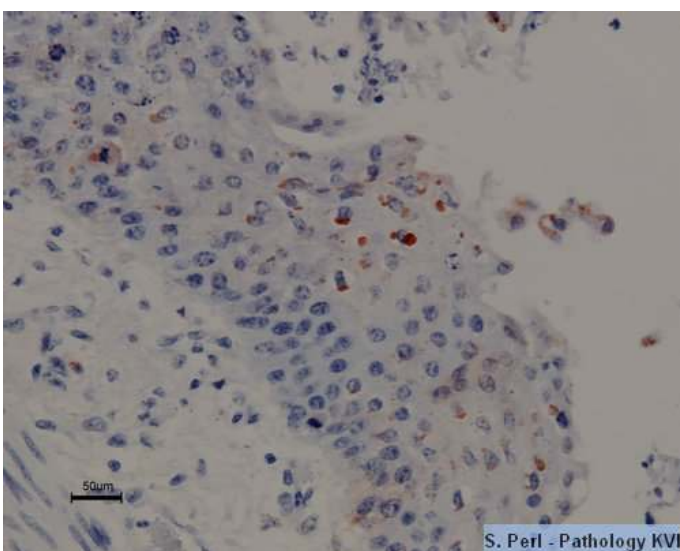
Buccal mucosa, necrotic stomatitis. Intracytoplasmic eosinophilic inclusion bodies are seen in some of the squamous epithelial cells



Intestinal crypts: Immunohistochemistry for PPR. positive staining (monoclonal antibody)



Intestinal crypts: Immunohistochemistry for PPR. positive staining (monoclonal antibody)



Oral mucosa: immunohistochemistry for PPR. positive staining (monoclonal antibody)