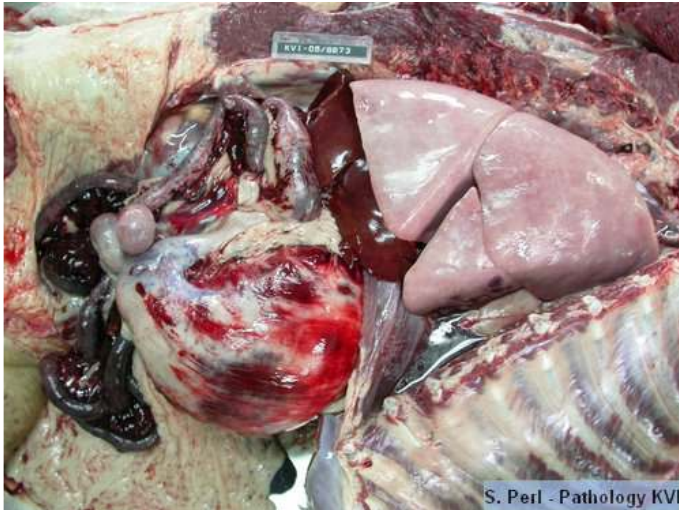
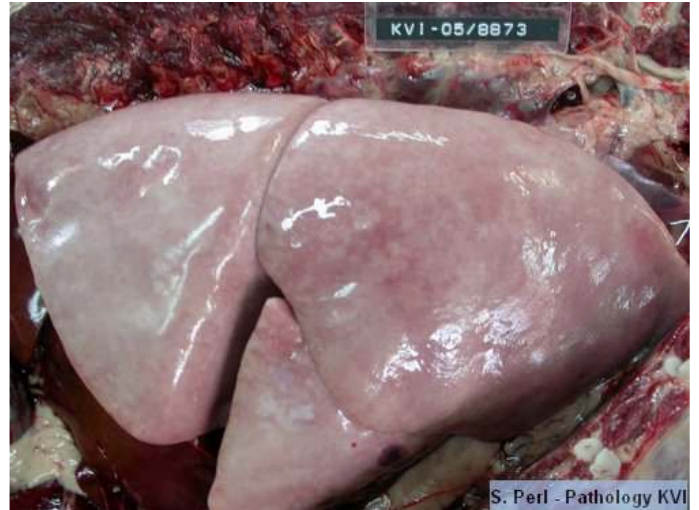


Pathological lesions in various diseases

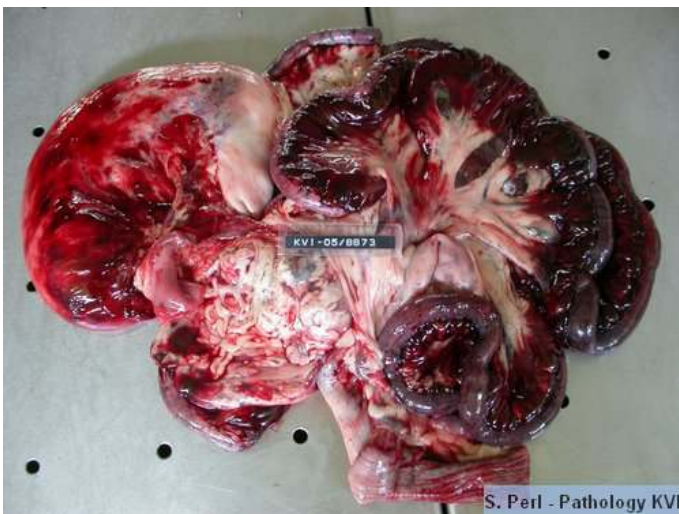
1. Heat stroke (hyperthermia) in a large breed dog



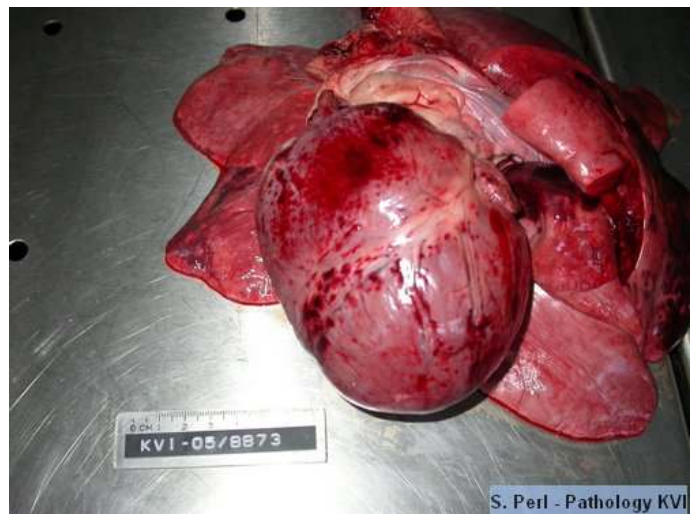
Diffuse ecchymotic hemorrhages on the serosa of the stomach



Hyperinflated lung



Diffuse congestion and hemorrhages in the small intestine



Multifocal petechial and ecchymotic hemorrhages on the heart