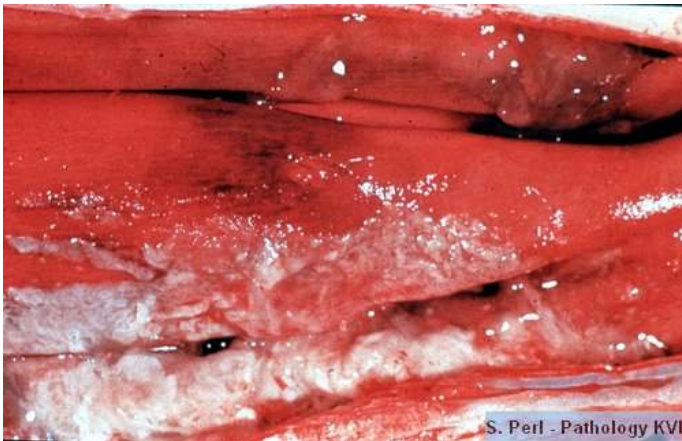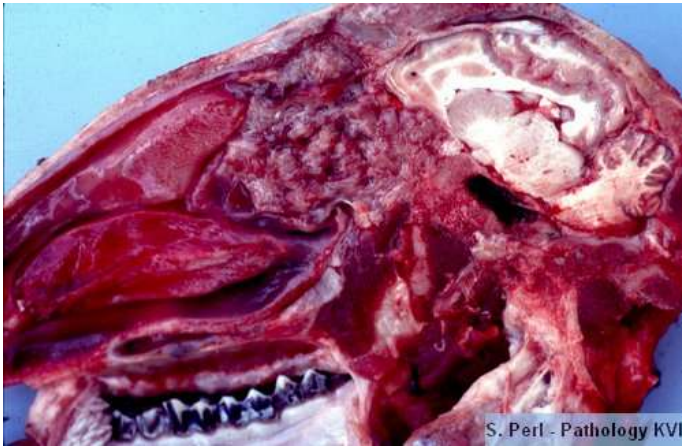


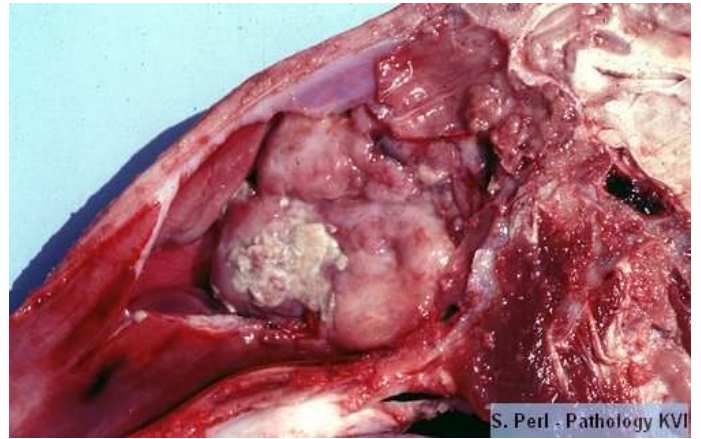
Nasal cavity



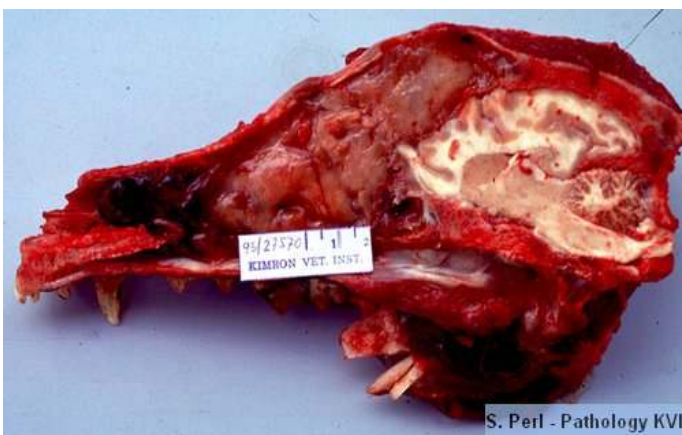
Fibrinous rhinitis, nasal conchae of a calf (IBR)



Endemic ethmoidal tumor (Enzootic nasal carcinoma), midsagittal section, head sheep



Nasal adenocarcinoma, Endemic ethmoidal tumor (Enzootic nasal carcinoma), midsagittal section of head, sheep



Nasal adenocarcinoma, midsagittal section, head ,7 year old dog.

