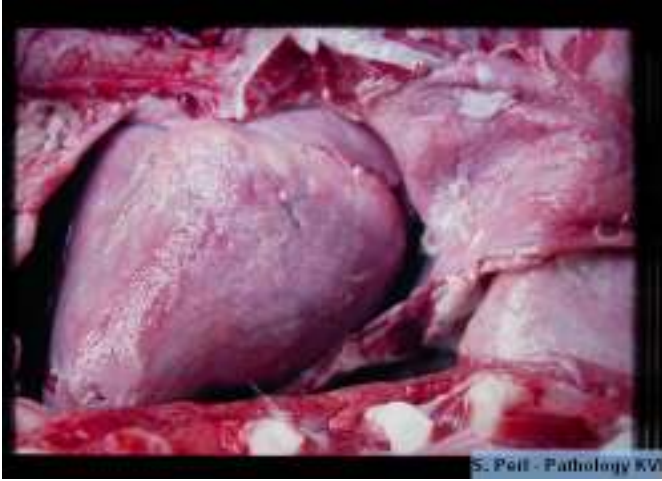
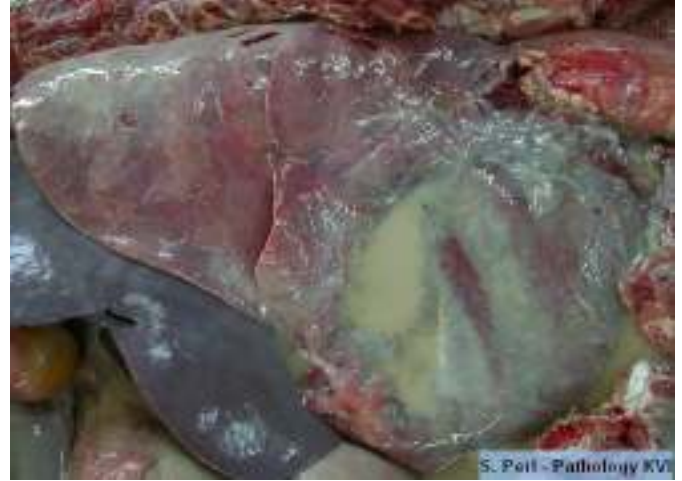

Pericardial disease

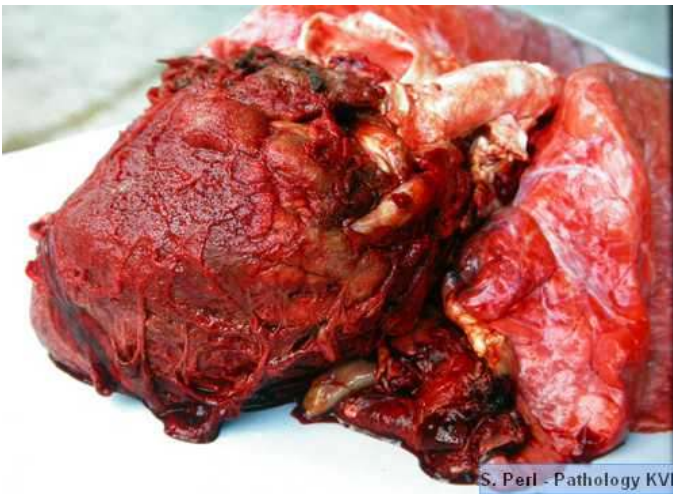A. Pericarditis



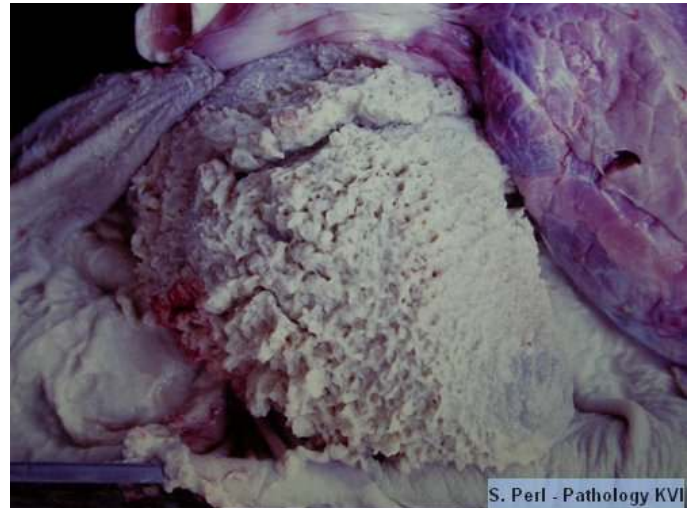1



2



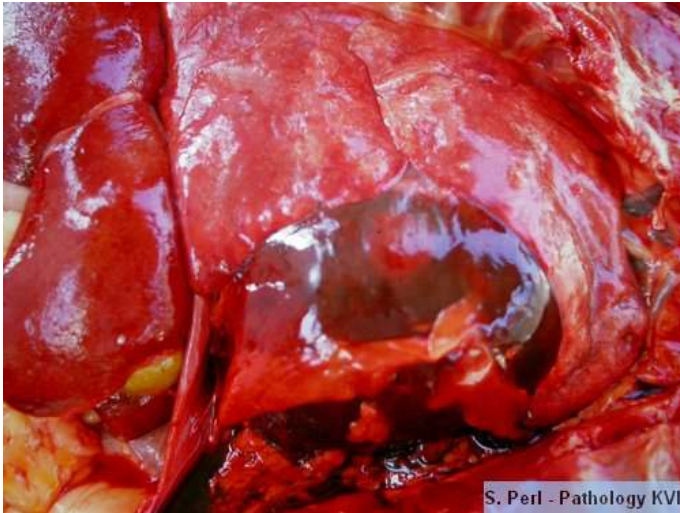
3



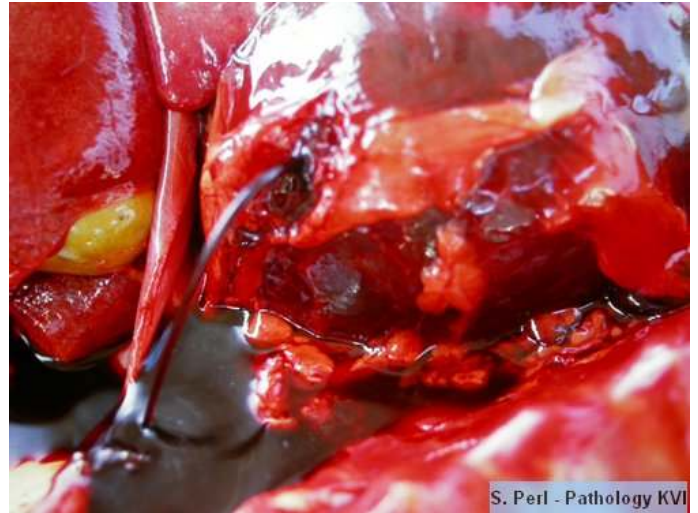4

1. Fibrinous pericarditis
2. Purulent pericarditis
3. Putrid, traumatic pericarditis
4. "Bread- and -butter" pericarditis

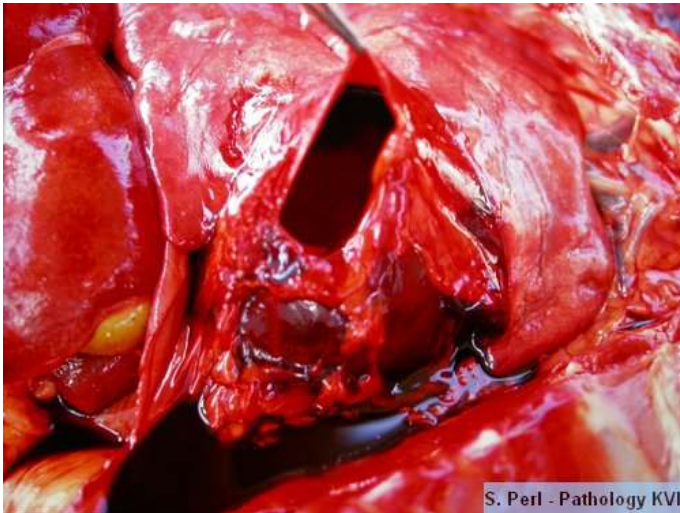B.Hemopericardium



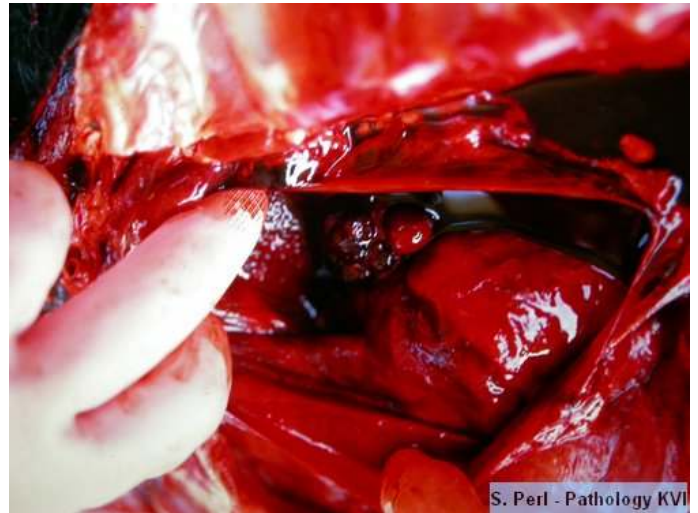1



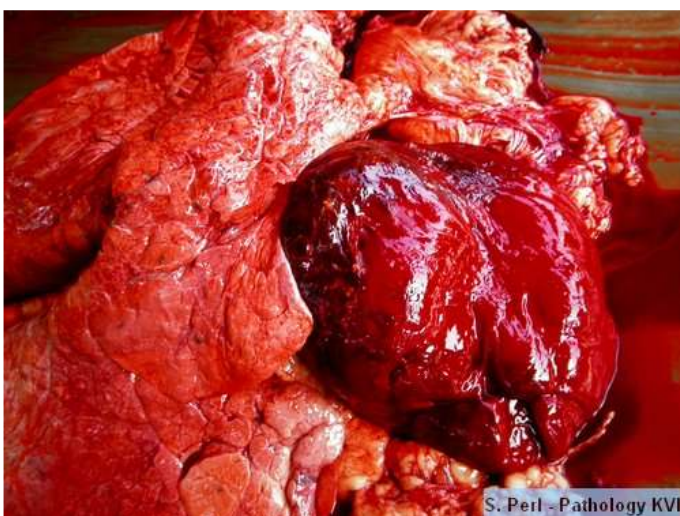2



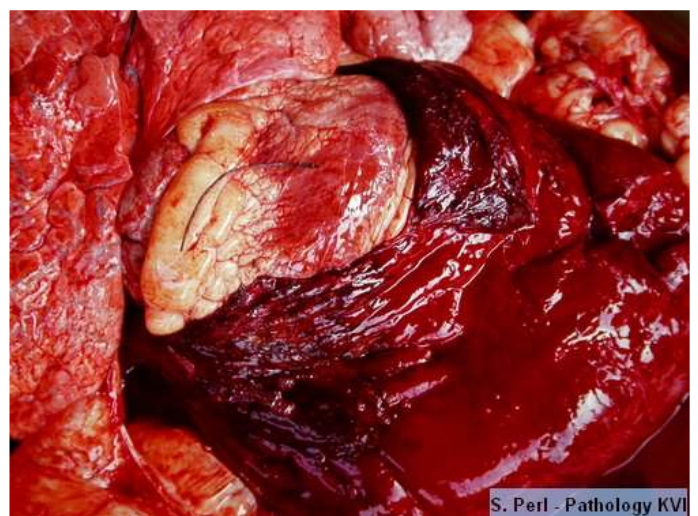3



4



5

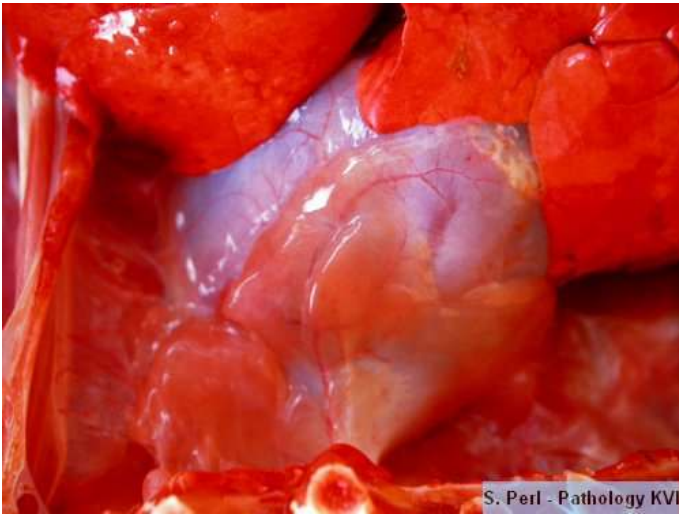

6

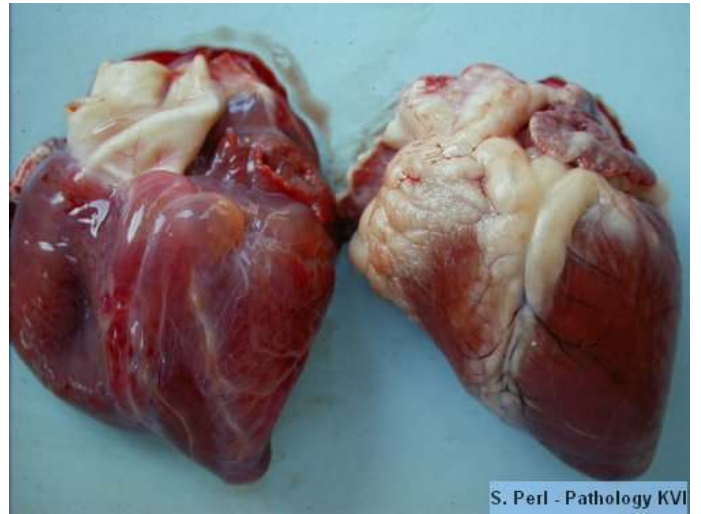1, 2, 3, 4. Accumulation of pure blood in the pericardial cavity due to hemangiosarcoma

5, 6. Hemopericard due to trauma at the coronary artery

C. Serous atrophy of pericardial fat



1

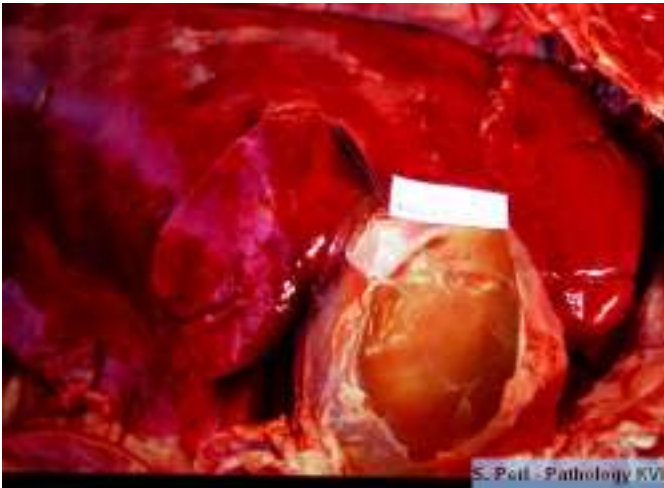


2

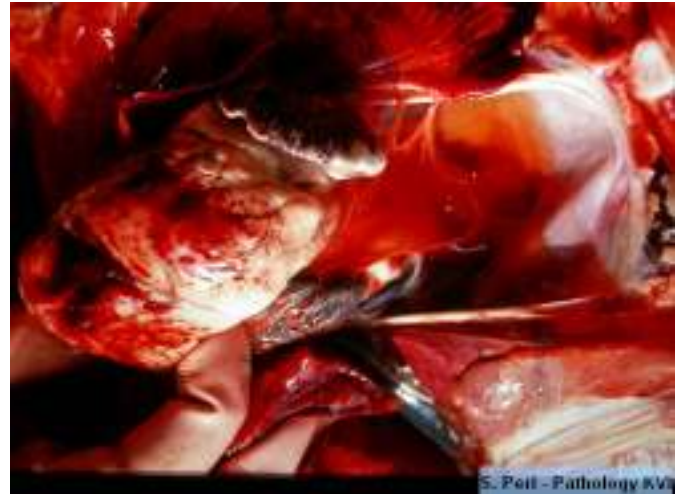1. Gelatinous masses on the pericardium

2. Gelatinous masses on the epicardium – heart at the left compared to a normal ovine heart

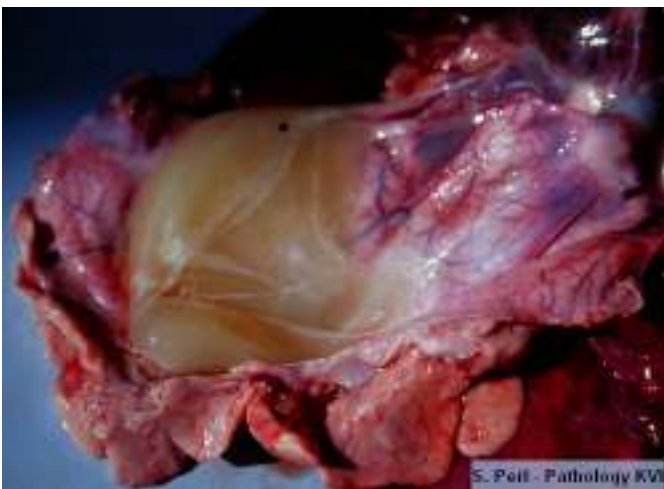D. Enterotoxemia, clostridial



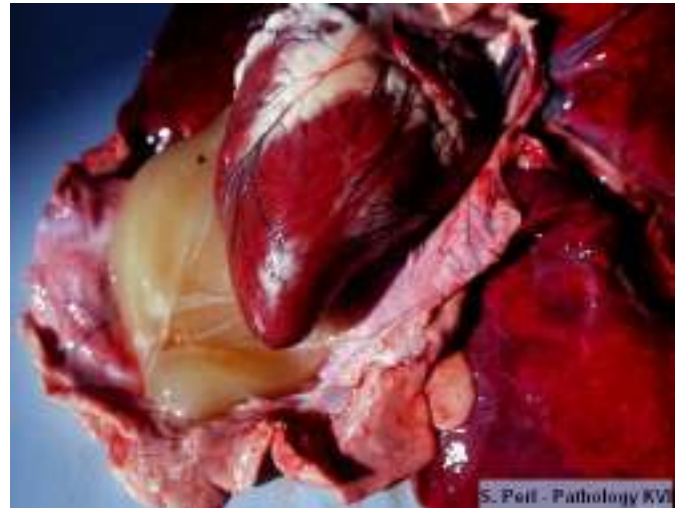1



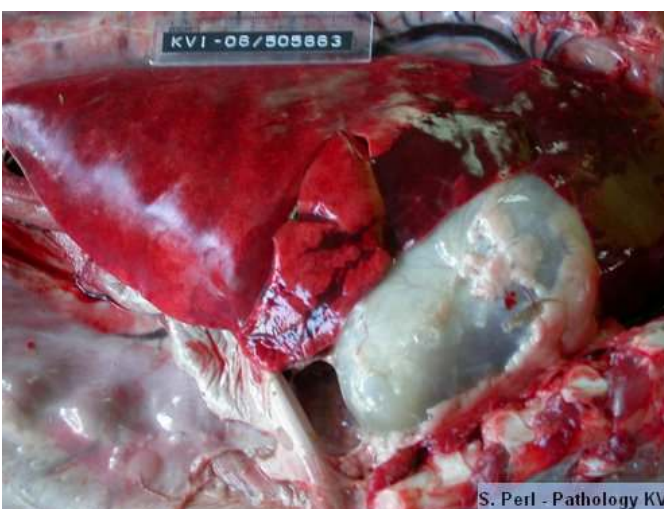
2



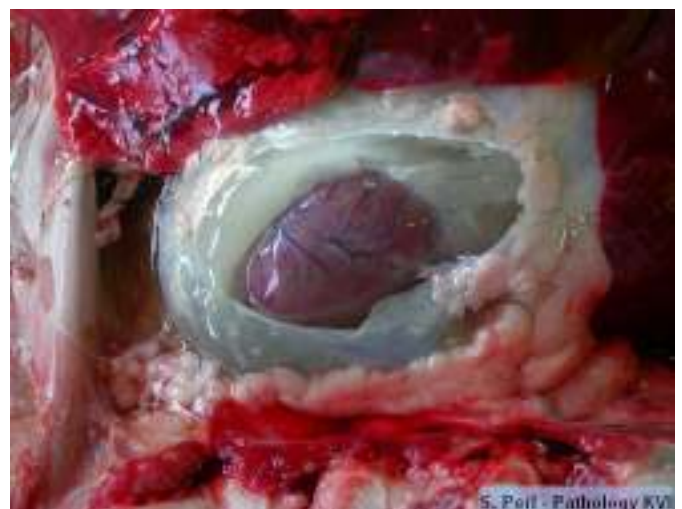
3



4



5



6

- 1,3,4,6. Gelatinous fluid in the pericardial sac
2. Hemorrhages on the epicardium and gelatinous fluid in the pericardium
5. Distended pericardial sac containing gelatinous fluid (6)