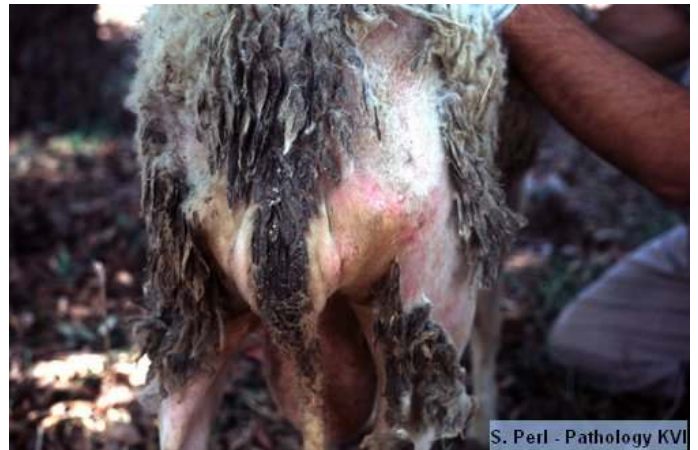

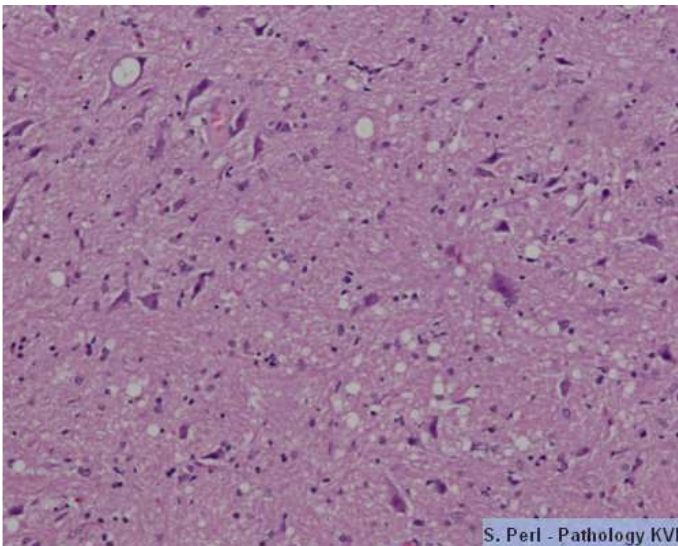
Scrapie



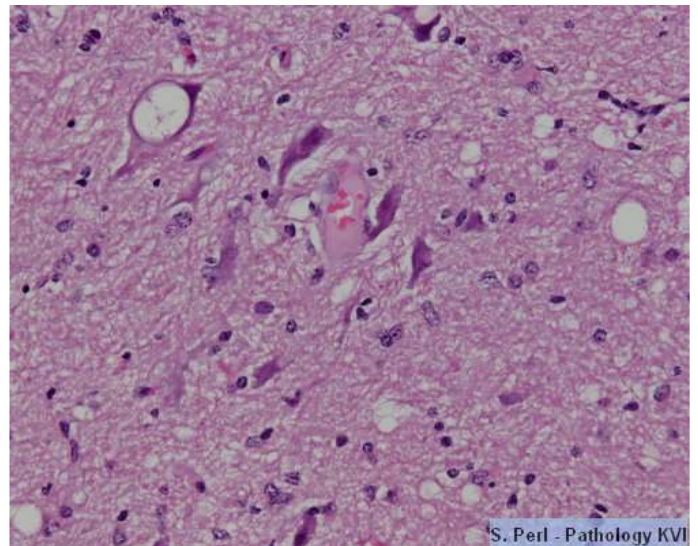
Loss of wool in a sheep



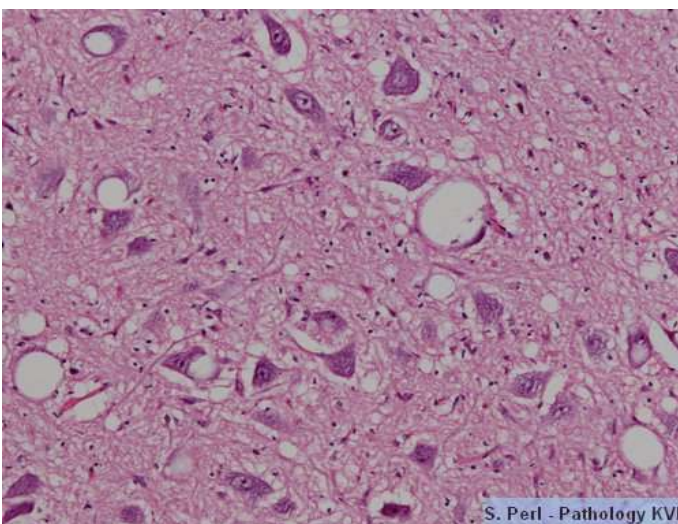
Loss of wool in a sheep and signs of scratching because of pruritus



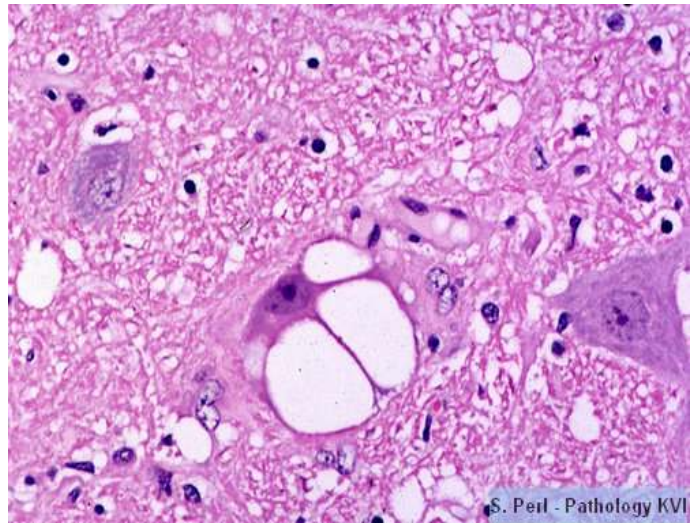
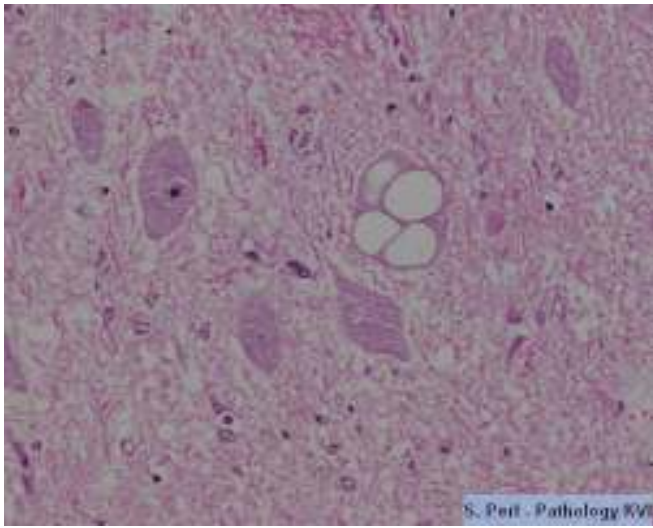
Neuron with a clear vacuole, spongiosis in the neuropil



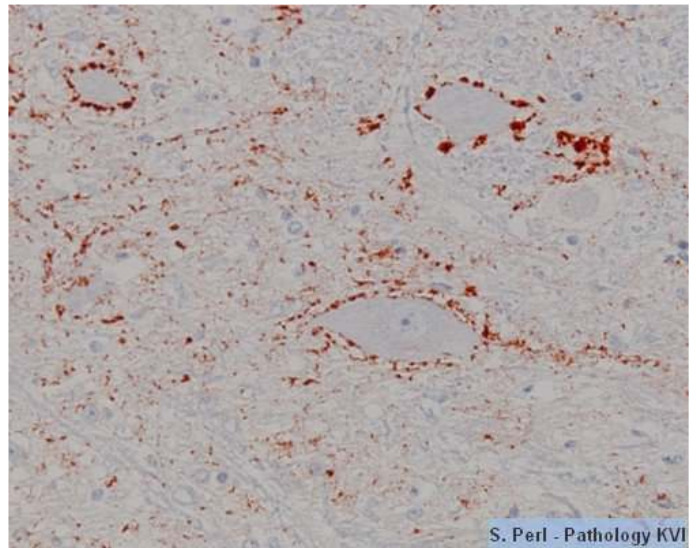
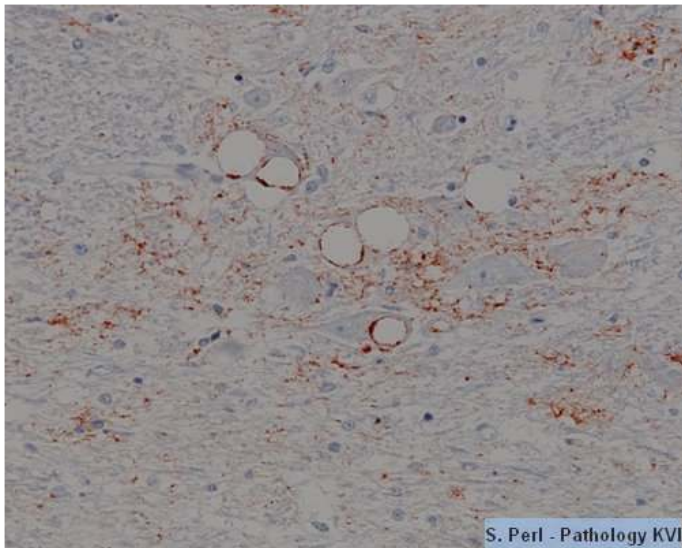
Neuronal cell bodies contain clear vacuoles



Spongiform encephalopathy



A neuron with more than one vacuole



Positive staining for scrapie by immunohistochemistry